 ISSN : 2230-7109 (Online) | ISSN : 2230-9543 (Print)

Histopathological Image Analysis for Breast Cancer Diagnosis : A Review

[1]Dr. V. R. Udupi, [2]Shabanam S.Tamboli, [3]Patil V. A, [4]Tamboli A. S
[1]Dept. of Electronics & Telecommunication Engineering, GIT, Belgaum, India
[2]Dept. of Electronics & Telecommunication Engineering, ADCET, Ashta, India
[3,4]Dept. of Electronics & Telecommunication Engineering, Shivaji University, Kolhapur, Maharashtra, India

Abstract
The characterization and quantitative description of histological images is not a simple problem. To reach a final diagnosis, usually the specialist relies on the analysis of characteristics easily observed, such as cells size, shape, staining and texture, but also depends on the hidden information of tissue localization, physiological and pathological mechanisms, clinical aspects, or other etiological agents. Over the past decade, dramatic increases in computational power and improvement in image analysis algorithms have allowed the development of powerful computer-assisted analytical approaches to radiological data. This paper reviews the recent state of the art CAD technology for digitized histopathology. In this paper we are going to review different methods available for breast cancer diagnosis.

Keywords
Breast Cancer, CAD, infrared thermal imaging, thermogram, image segmentation, edge detection, MRI.

I. Introduction

Several world and national non-profit organizations have engaged in finding day to day solution to cancer deaths. However, a considerable number of women victims of breast cancer have persisted. For 2008, the American Cancer Society (ACS) and the National Cancer Institute (NCI) estimated 182,460 new breast cancer cases and about 40,480 will die of breast cancer in the United States (Breast Cancer New Cases and Deaths) [1]. This is a big number taking into account the modern technology and the availability of advanced research institutions. More precisely, women in developing countries represent a substantial number of women who die from breast cancer every year due to a lack of the improved early detection and diagnosis methods with the appropriate equipment. Even small improvements in the early diagnosis and treatment of breast cancer would likely save thousands of lives annually. Breast cancer has been known for decades to be the most common type of cancer among women. The incidence of breast cancer in India is on the rise and is rapidly becoming the number one cancer in females. India accounts for nearly six percent of deaths due to breast cancer in the world. One out of every 22 women in India is diagnosed with breast cancer [2]. Recent studies have determined that the key to breast cancer survival rests upon its earliest detection possible. A part of the body is called cancerous when its cells start to grow in an out of control manner. Breast cancer is a tumour that starts from breast cells. Breast tumours can be malignant or benign. It is believed that benign tumours are not life threatening in most cases. Therefore, only malignant breast tumours are addressed as breast cancer. A malignant tumour is a group of cancer cells that invade surrounding tissues or spread to distant areas of the body. This cancer is specific for women but it rarely occurs in men too.

In this paper we are going to review various breast cancer detection methods. The aim of this paper is to provide an overview of CAD systems and related techniques developed in recent years. It is also intended to draw the attention of more research scientists to the research field of CAD for breast cancer, and advance research on the detection and diagnosis of breast cancer and related techniques, such as image processing, computer technology, and radiological imaging.

II. Literature Review

Breasts are conical structures lying on the anterior and lateral chest wall. In general, the second or third rib (level of the clavicle) marks the superior boundary of the breast which extends inferiorly the sixth or seventh rib. Usually the breast extends from the lateral border of the sternum to the mild-axillary line, but occasionally to the midline or the anterior border of the latissimus dorsi (Breast Cancer). X-ray mammography and clinical breast examination (CBE) are the current gold standards of breast cancer screening. Ultrasound and MRI are also used as secondary screening tools to elucidate suspicious findings from the X-ray mammogram. Other non-optical imaging techniques include positron emission tomography (PET), electrical impedance tomography (EIT), and thermal imaging.

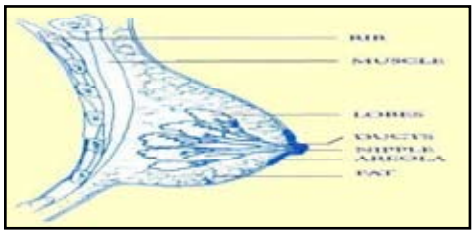

Fig. 1: Anatomy of the female breast

A segmentation algorithm, in a mammographic context, is an algorithm used to detect something, usually the whole breast or a specific kind of abnormalities, like micro-calcifications or masses. It is generally accepted that the detection of masses is technically more difficult than the detection of micro-calcifications, because masses cam be simulated or obscured by normal breast parenchyma [3]. Moreover, there is a large variability in these lesions, which is reflected in morphology variation (shape and size of the lesions), and also in the large number of features that have been used to detect and classify them. Although segmentation of the breast from back ground is not the main goal our research, this kind of segmentation is a fundamental step in mammogram image analysis because the techniques to be used in later section of system are only applied to the breast area. The aim of breast profile segmentation is to separate the breast from other objects in the mammogram with a minimum loss of breast tissue. In general two independent steps performed. The first one aims to segment the background an annotations from the whole breast area, while the second one involves separating the pectoral muscle (when present)

from the rest of the breast area. Approaches to the breast background segmentation ranges from histogram thresholding followed by smoothing [4] to polynomial modeling [5] or, more recently, active contour approaches [6]. Typical strategies to segment the pectoral muscle have been based on straight line estimation using Hough Transform [7] or direct detection using Gabor filters as edge detectors [8].

Segmentation techniques can be divided into supervised and unsupervised approaches. Supervised segmentation, also known as model based segmentation, relies on prior knowledge about the region of interest to be segmented and optional background regions. The prior information is used to determine if specific regions are present within an image or not. Unsupervised segmentation consists of partitioning the image into a set of regions which are distinct and uniform with respect to specific properties, such as grey level, texture or color. Classical approaches to solve unsupervised segmentation are divided in three major groups:

Region based methods, which divide the image into homogeneous and spatially connected regions.Contour-based methods, which rely on finding the boundary or regionsClustering methods, which group together those pixels having similar properties and might result in non-connected regions. Region-based segmentation relies on the principle of homogeneity, which means that there has to be at least one feature which remains uniform for all pixels within a region. Two basic strategies of region-based methods are the well known region growing and split and merge methods. Region growing based on the propagation of an initial seed point according to a specific homogeneity criterion, iteratively increasing the size of the region. Region growing algorithms have been widely used in mammographic mass segmentation. On one of the work [9], researcher developed a semi-automatic region growing approach, in which the growing step was automatically computed after radiologist had manually placed the seed point. In another attempt of segmentation [10], fuzzy version of the region growing algorithm was introduced. This approach was pixel based (the homogeneity criterion is evaluated for each pixel), and no prior shape was considered. It is based on considering the uncertainty present around the boundaries of tumor region, with the aim to preserve the transition between mass and normal tissue. The split and merge technique for mammographic mass segmentation has been used in [11], beginning with a hand –selected region of the interest containing a single mass, it approximates boundary of region by polygons. Clustering method for segmentation was used as a generalization k-means that included spatial information to refine an initial segmentation, which was achieved by using adaptive thresholding. Alternative clustering algorithms used for mammographic mass segmentation are the fuzzy C-Means (FCM) algorithm [12] and Expectation Maximization (EM) algorithm. One of the earliest approaches to mass segmentation was work mentioned in [13], which was based on a multi- resolution fuzzy pyramid linking approach, a data structure in which the input image formed the basis of the pyramid and each subsequent level [lower resolution) was sequentially constructed. The links between each node and its four parents were propagated using fuzzy function to upper levels. In literature, different approaches based in the use of only histogram information have been proposed for classifying breast tissue. Several other researchers have focused their attention on the use of texture feature to describe breast density. In one of the research, they segmented mammograms into density regions based on a set of co-occurrence matrices and the subsequent density classification used relative area of the density regions as the feature space. From review it is clear that segmentation is one of the important tasks in cancer detection. Several segmentation algorithms are available. Region, Texture, histogram, or other features may be used as a basis for segmentation.

III. Detection And Diagnosis Of Breast Cancer

A. Using Mammography

There are several imaging techniques for examination of the breast, including magnetic resonance imaging, ultrasound imaging, and X-ray imaging. Mammography is a specific type of imaging that uses a low-dose X-ray system to examine the breast, and is currently the most effective method for detection of breast cancer before it becomes clinically palpable [14]. Mammography offers high-quality images at a low radiation dose, and is currently the only widely accepted imaging method used for routine breast cancer screening. Current guidelines of the American Cancer Society (ACS) recommend that women aged 40–49 years have a routine mammogram every one to two years, with the first beginning at age 40 [15].

Currently, there are two types of mammography [16-18]: one is film mammography and the other is digital mammography. In film mammography, the image is created directly on film, whereas digital mammography takes an electronic image of the breast and stores it directly on a computer [16]. Although both types of mammography have their advantages and disadvantages, digital mammography has some potential advantages over film mammography. Compared to digital mammography, screen-film mammography has some limitations, which include [19]: 1) limited range of X-ray exposure; 2) image contrast cannot be altered after the image is obtained; 3) the film acts as the detector, display, and archival medium; and 4) film processing is slow and introduces artifacts. All of these limitations have pushed researchers further to develop advanced techniques for digital mammography. Digital mammography is overcoming and will continue to overcome the limitations of film mammography described before, and will have the following potential advantages [19]: 1) wider dynamic range and lower noise; 2) improved image contrast; 3) enhanced image quality; and 4) lower X-ray dose.

Although digital mammography has many potential advantages over traditional film mammography, clinical trials show that [20] the overall diagnostic accuracy levels of current digital and film mammography are similar when used in breast cancer screening. However, digital mammography may be more effective than screen-film mammography for certain women [21-22]. For example, Spurgeon [21] showed that digital mammography depicts more tumors than screen-film mammography, especially lesions seen as microcalcifications (MCs). Pisano et al. [20] showed that digital mammography is more accurate in women under the age of 50, women with radio graphically dense breasts, and premenopausal women.

There are two types of examinations performed using mammography: screening mammography and diagnostic mammography. Screening mammography is performed to detect breast cancer in an asymptomatic population [23]. Screening mammography generally consists of four views, with two views of each breast: the craniocaudal (CC) view and the mediolateral oblique (MLO) view. The aim of diagnostic

mammography is to examine a patient who has already demonstrated abnormal clinical findings, such as a breast lump [23]. Similar to screening mammography, each breast examined using diagnostic mammography may also have two views. Additional diagnostic mammography may offer an in-depth look at suspicious areas. Diagnostic mammography is often performed as a follow up examination of an abnormal screening mammography in order to determine whether the area of concern on the screening examination needs additional breast imaging or a biopsy to determine whether the woman has breast cancer [23]. The adoption of mammographic examinations, especially screening mammography, has been proven to increase the rate of detection of cancer and reduce the rates of morbidity and mortality [14].

One of the difficulties with mammography [24] is that mammograms generally have low contrast. This makes it difficult for radiologists to interpret the results. Studies [25, 26] have shown that mammography is susceptible to a high rate of false positives as well as false negatives, causing a high proportion of women without cancer to undergo further clinical evaluation or breast biopsy, or miss the best time interval for the treatment of cancer. Several solutions have been proposed to increase the accuracy, specificity, and sensitivity of mammography and reduce unnecessary biopsies.

Double reading of mammograms [27-28] has been advocated to reduce the proportion of missed cancers. The basic idea of double reading is to have two radiologists read the same mammograms. According to Warren and Duffy [28], double reading can contribute significantly to high sensitivity and effective screening. However, the workload and cost associated with double reading are high. Instead of double reading, CAD, which is referred to as the "second pair of eyes of the radiologists," is aimed to be used to aid radiologists in their interpretation of mammograms. With a CAD system, only one radiologist is needed to read each mammogram rather than two. The adoption of a CAD system could reduce the experts' workload. It has been proven that CAD systems can improve the detection rate of cancer in its early stages. For example, research by Morton et al. [29] indicates that the use of CAD improved the detection of breast cancer with a 7.62% increase in the number of breast cancers detected, with a small but acceptable increase of 0.93% in the recall rate, and a minimal increase in the number of biopsies with benign or negative results. Brem et al. [30] reported that use of a CAD system significantly improved the detection of breast cancer by increasing the radiologist's sensitivity by 21.2%.

4. Advantages & disadvantages of X-ray Mammography

Due to its low cost, it is suitable for mass screening program. Mammography has its limitations. It is less reliable on dense breast of young women or women underwent a surgical intervention in the breast because glandular and scar tissues are as radiopaque as abnormalities. Furthermore, there is low dose X-Ray radiation.

In some cases MRI may be used as an alternative to mammography.

B. MRI of the Breast

Magnetic Resonance Imaging is the most attractive alternative to Mammography. MRI is sensitive for detecting some cancers which could be missed by mammography. In addition, MRI can help radiologists and other specialists determine how to treat breast cancer patients by identifying the stage of the disease. It is highly effective to image breast after breast surgery or radiation therapy. To be effective, contrast-enhanced breast MRI is carried out by injecting in the patient's body of a paramagnetic contrast agent. This method is based on the hypothesis that, after the injection of the agent, abnormalities enhance more than normal tissues due to their increased vascularity, vascular permeability and interstitial spaces [35] MRI forms 3D uncompressed image. It can perform with all women including who are not suitable for mammography, such as young women with dense breast and women with silicone-filled breast implants.

1. Advantages & disadvantages of MRI

Since it uses magnetic fields, MRI has no harmful effects on human bodies. However, MRI takes rather long time to perform and has high cost which is more than ten times greater than mammography. Its low resolution limits its application to very small lesions or microcalcifications.

C. Thermography

Infrared thermal imaging or thermography is a promising screening tool as it is able to warn women of breast cancer ten years in advance. However, interpretation of a thermogram can be inconsistent. In order to improve the accuracy of preliminary breast cancer screening using thermogram, image segmentation is proposed as an automatic approach for analysis of infrared thermal images. Edge detection and Hough transform are outlined for asymmetry analysis of heat patterns in contralateral breasts [36].

The approach will be effectual and feasible and would be of great practical value in diagnosing the asymmetric abnormalities for breast using infrared images and will help as a useful second opinion.

D. First Order Statistical Feature to classify Thermal Images

The abnormalities of breast thermograms with tabulated the first order statistics methods which are the mean values, standard deviation values, skewness values, and kurtosis values with thermal camera Fluke as a tool for capturing images, after the applications of wiener filter and histogram equalization to enhance the images and region of interest to obtain the specific object. We have used statistical features method to classify types of thermograms after image processing. The results show that the method is promising to detect the abnormality on the breast thermogram images. The normal breast thermograms have minimum standard deviation value and skewness value which differ from those abnormal thermograms in the early stage of breast cancer and the significantly from the advanced of breast cancer.

E. Forward Scattering Radar Technique

An initial investigation for breast cancer detection using a special mode of bistatic radar system known as Forward Scattering Radar (FSR). The proposed method analyzes the Doppler frequency in the received signal scattered from the tumor for cancer detection and localization. Three systems of architectures were analyzed which determined by the mechanical movement of transmitter or receiver or both [37]. An initial simulated result by using CST Microwave Studio as a

feasibility study of utilizing FSR for breast cancer detection. It is shown that by investigating the unique character of Radar Cross Section (RCS) for breast tissue and tumor of FSR a cancer can be predicted. Electromagnetic model including fatty tissue and a tumor were simulated to obtain RCS parameter and analyzed as well as compared with whose fatty tissue without cancerous lesion to pinpoint the presence of tumor from its FSR signature. The result shows a significant different between these two models in FS RCS.

F. Computer-Aided Detection and Diagnosis of Breast Cancer

CAD, which integrates diagnostic imaging with computer science, image processing, pattern recognition, and artificial intelligence technologies [31], can be defined as a diagnosis [32] that is made by a radiologist who uses the output from computerized analysis of medical images as a "second opinion" in detecting lesions and making diagnostic decisions. In the past several years, CAD systems have drawn much attention from both research scientists and radiologists because of the associated challenging research topics and potential clinical applications. There are two types of CAD systems based on mammographic technologies: one is based on the conventional screen-film mammographic technology and the other is based on digital mammographic technology. In the first type of CAD systems, the films are scanned, digitized, and saved on the computer for further examination. The second type of systems use full-field digital mammographic (FFDM) technology, which is expected to provide a higher signal-to-noise ratio, a higher detection quantum efficiency, a wider dynamic range, and a higher contrast sensitivity than digitized film mammograms [33]. Although FFDM technology is expected to be superior to the conventional film-based mammographic technology, the results obtained in a recent study show, with reasonable certainty, that there is no difference in the accuracy between FFDM and screen-film mammography, in particular, for asymptomatic women [34]. Commercial CAD systems based on these two types of mammographic technology have been reported to have similar performance [33]. Instead of X-rays microwaves can also be used for breast cancer detection.

G. Time Reversal Imaging

Microwave radiation is known to be a potential diagnostic imaging tool for breast cancer detection that could complement the standard X-ray mammography. Electromagnetic radiation waves undergo multiple scattering due to the in homogeneities of biological tissues. The imager consists of two linear antenna arrays, the imaging algorithm has described in the (discrete) frequency domain because time reversal in the time domain is equivalent to phase conjugation in the frequency domain. Time reversal imager exploits successfully the multiple path electromagnetic scattering to achieve higher resolution and robustness than the direct subtraction beamforming imager [38].

1. Advantages

Time reversal beamforming imager achieves better accuracy, higher robustness, and increased resolution than the conventional direct subtraction beamforming imager.

H. Self Similar Fractal Method

This is a method for medical image enhancement based on the well established concept of fractal derivatives and selecting image processing techniques like segmentation of an image with self similar properties. The concept of a fractal is most often associated with geometrical objects satisfying two criteria: self-similarity and fractional dimensionality [39]. The self similar fractal approach, on the contrary, uses the initial discrete image data directly. Based on the idea that the underlying continuous process might not be possible to recover, the relevant information is extracted directly from the singularities. The advantage is that no information is lost or introduced by the smoothing process, which is an important feature in applications like edge detection, segmentation and texture classification, particularly in medical diagnosis. The drawback is that this approach might be more sensitive to noise.

I. Using Boosted Decision Trees

Decision tree (DT) is one of the popular and effective data mining methods. DT provides a pathway to find "rules" that could be evaluated for separating the input samples into one of several groups without having to express the functional relationship directly. They avoid the limitations of the parametric models and are well suited for the analysis of nonlinear events. Recently invented DT model algorithm (C5.0) [40] is used for the diagnosis of breast cancer using cytologically proven tumor dataset. The objective is to classify a tumor as either benign or malignant based on cell descriptions gathered by microscopic examination. The classification performance of C5.0 DT is evaluated and compared to the one that achieved by radial basis function kernel support vector machine (RBF-SVM). The dataset has been partitioned by the ratio 70:30% into training and test subsets respectively. Experimental results show that the generalization of the C5.0 DT has been increased radically using boosting, winnowing and tree pruning methods. The C5.0 DT model has achieved a remarkable performance with 98.95% classification accuracy on training subset and 100% of test one while RBF-SVM has achieved 100% success on both training and test subsets.

In all above methods image processing is used as a main tool. So, we will go for study of image processing tools.

IV. Image Processing Tools for Tumor Detection in Mammograms

Currently, there are several image processing methods proposed for the detection of tumors in mammograms. Various technologies such as fractal analysis [41], discrete wavelet transform and Markov random field have been used. In [42], multiple circular path convolution neural network architecture has been designed for the analysis of tumor and tumor-like structures. In [43], Petrick et al. reported a two-stage adaptive density-weighted contrast enhancement (DWCE) algorithm for tumor detection in mammograms. These studies focus on two types of breast cancer: micro calcifications and masses. The performance of various methods reported in the literature in most cases has been measured on different data sets. The choice of database used by these researchers can influence the performance of their algorithms significantly [44].

A. Mathematical Morphology

One of the most rewarding areas of Image processing is Mathematical Morphology. Set theory forms the substratum of Mathematical Morphology. The objects in an image are analogous to the sets in Mathematical Morphology. Some of the premier operations that are instrumental for diverse image processing problems include erosion, dilation, opening and closing [45].

B. Morphological Segmentation

The proposed approach utilizes mathematical morphology operations for the segmentation. The morphological operations are applied on the grayscale mammography images to segment the abnormal regions [47, 48]. Erosion and dilation are the two elementary operations in Mathematical Morphology. An aggregation of these two represents the rest of the operations [46].

C. FUZZY C-Means Algorithm

The FCM algorithm, also known as Fuzzy ISODATA, is one of the most frequently used methods in pattern recognition [48]. It is based on the minimization of the objective function (1) to achieve a good classification. J is a squared error clustering criterion, and solutions of minimization of (1) are least-squared error stationary points of J. The morphological operations and FCM is a new approach, using this we have successfully detected the breast cancer masses in mammograms. The results indicate that this system can facilitate the doctor to detect breast cancer in the early stage of diagnosis process.

V. Conclusion

CAD is an important tool for early detection of breast cancer. A significant amount of work has been done in this area over the past 20 years. Compared with double reading, CAD can reduce the workload of radiologists. However, the performance of current CAD systems still needs improvements to fully meet the requirements for routine clinical applications. In the move toward an effective CAD system for breast cancer detection, many techniques have been developed. We described some basic concepts related to breast cancer detection and diagnosis, and reviewed many key techniques for breast cancer detection of calcifications, masses. Although significant progress has been made over the last 20 years, much work still needs to be done to develop more effective CAD systems. Effective and efficient CAD systems should lead to early detection of breast cancer and improved prognosis for those affected by the disease.

References

[1] S. H. Landis, T. Murray, S. Bolden, P. A. Wingo, “Cancer Statistics 1999”, Cancer J. Clin. 49, pp. 8-31 (1999).

[2] Sherring, Varsha, “Mediating Breast cancer in India”, NCA 94th annual convention, San Diego, CA, 2009.

[3] L.W. Basset, R. H. Gold, “Breast Cancer Detection : Mammograms and Other Methods in Breast Imaging”, Grune & Stratton, New York , 1987

[4] J. J. Heine , M. Kallergi , S.M. Chetelat, L.P. Clarke, “Multi-resolution wavelet approach for separating the breast region from the back ground in high resolution digital mammography”, In Proc. International Workshop on digital Mammography, pp. 295-298, 1998.

[5] R. Chandrashekahr, Y. Attikiouzel, “ Gross segmentation of mammograms using polynomial model”, In Proc. International Conference IEEE Engineering in Medicine and Biology Society, vol 3, pp. 1056-1058.

[6] R.J. Ferrari, R.M. Rangayyan, J.E. L. Desautels,“ Segmentation of Mammogram: Identification of the skin boundary and pectoral muscle", In Proc. International Workshop on digital Mammography, pp. 573-579, 2000.

[7] S.M. Kwok, R Chandrashekhar, Y. Attikiouzel, M.T. Rickard, “Automatic pectoral muscle segmentation on mediolateral oblique view mammograms”, IEEE Transactions on Medical Imaging 23(9), pp. 1129-1140, 2004.

[8] R.J. Ferrari, R.M. Rangayyan, J.E. L. Desautels, R. A Borges and A.F. Frere,” Automatic identification of the pectoral muscle in mammograms”, IEEE Transactions on Medical Imaging 23(2), pp. 232-245, 2004.

[9] Z. Huo, M.L. Giger, C.J. Vyborny, U. Bick, P. Lu , D.E. Wolverton, R. A Schmidt, “Analysis of speculation in the computerized classification of mammographic masses”, Medical Physics, 22(10), pp. 1569-1579, 1995.

[10] D. Guliato, R. M. Rangayyan, W. A. Carnielli, J.A. Zuffo, J.E.L. Desautels, “Segmentation of Breast tumours in mammograms by fuzzy region growing”, In Proc. International Conference IEEE Engineering in Medicine and Biology Society, vol 20, pp. 1002-1005, 1998.

[11] R.M. Rangayyan, E.N.M. El-Faramawy, J.E.L. Desautels, O.A. Alim, "Measures of acutance and shape for classification of breast tumours”, IEEE Transactions on Medical Imaging 16(6), pp. 799-810, 1997.

[12] J.C. Bezdek , “Pattern Recognition with Fuzzy Objective Function Algortihms”, Plenum Press, New York, 1981.

[13] D. Brzakovic, X. M. Luo, P. Brzakovic, “An approach to automated detection of tumors in mammograms”, IEEE Transactions on Medical Imaging, 9(3), pp. 233–241, 1990.

[14] K. H. Ng, M. Muttarak, “Advances in mammography have improved early detection of breast cancer”, J. Hong Kong College Radiol., vol. 6, no. 3, pp. 126–131, 2003.

[15] C. Lewis, “FDA sets higher standards for mammography", FDA Consum., vol. 33, no. 1, pp. 13–17, 1999.

[16] [Online] Available: http://www.cancer.gov/cancertopics/ factsheet/ DMISTQ. 2005.

[17] D. Gur, “Digital mammography: Do we need to convert now?”, Radiology, vol. 245, no. 1, pp. 10–11, 2007.

[18] E. D. Pisano, R. E. Hendrick, M. Yaffe, E. F. Conant, C. Gatsonis, “Should breast imaging practices convert to digital mammography? A response frommembers of theDMIST executive committee”, Radiology, vol. 245, no. 1, pp. 12–13, 2007.

[19] W. Yang, “Digital mammography update”, Biomed. Imag. Intervention J., vol. 2, no. 4, pp. 45–12, 2006.

[20] E. D. Pisano, C. Gatsonis, E. Hendrick, M. Yaffe, J. Baum, S. Acharyya, E. Conant, L. Fajardo, L. Bassett, C. D’Orsi, R. Jong, M. Rebner, “Diagnostic performance of digital versus filmmammography for breastcancer screening”, New England J. Med., vol. 353, no. 17, pp. 1773–1783, 2005.

[21] D. Spurgeon, “Digital mammography is more accurate only for certain groups of women”, Br. Med. J., vol. 331, no. 7518, pp. 653–653, 2005.

[22] M. Del, P. Mantellini, S. Ciatto, R. Bonardi, F. Martinelli, B. Lazzari, N. Houssami, "Full-field digital versus screen-film mammography:Comparative accuracy in concurrent screening cohorts", Amer. J. Roentgenol., vol. 189, no. 4, pp. 860–866, 2007.

[23] "NCI Cancer Fact Sheets(2007)", [Online] Available: http:// www.cancer.gov/ cancertopics/ factsheet/ Detection/ screening-mammograms.

[24] T.Wang, N. Karayiannis, "Detection of microcalcifications in digital mammograms using wavelets", IEEE Trans. Med. Imag., vol. 17, no. 4, pp. 498–509, 1998.

[25] R. Bird, T. Wallace, B. Yankaskas, "Analysis of cancers missed at screening mammography", Radiology, vol. 184, no. 3, pp. 613–617,1992

[26] K. Kerlikowske, P. Carney, B. Geller, M. Mandelson, S. Taplin, K. Malvin, V. Ernster, N. Urban, G. Cutter, R. Rosenberg, R. Ballard- Barbash, "Performance of screening mammography among women with and without a first-degree relative with breast cancer", Ann. Internal Med., vol. 133, no. 11, pp. 855–863, 2000.

[27] J. Brown, S. Bryan, R. Warren,"Mammography screening: An incremental cost effectiveness analysis of double versus single reading of mammograms", Br. Med. J., vol. 312, no. 7034, pp. 809–812, 1996.

[28] R. Warren, S. Duffy, "Comparison of single and double reading of mammograms, and change in effectiveness with experience", Br. J. Radiol., vol. 68, no. 813, pp. 958–962, 1995.

[29] M. Morton, D. Whaley, K. Brandt, K. Amrami, "Screening mammograms: Interpretation with computer-aided detection—Prospective evaluation", Radiology, vol. 239, no. 2, pp. 375–383, 2006.

[30] R. Brem, J. Baum, M. Lechner, S. Kaplan, S. Souders, L. Naul, J. Hoffmeister,"Improvement in sensitivity of screening mammography with computer-aided detection: A multiinstitutional trial", Amer. J. Roentgenol., vol. 181, no. 3, pp. 687–693, 2003.

[31] R. M. Rangayyan, F. J. Ayres, J. E. L. Desautels,"A review of computer-aided diagnosis of breast cancer: Toward the detection of early signs", J. Franklin Inst., vol. 344, no. 3/4, pp. 312–348, 2007.

[32] M. Giger, "Computer-aided diagnosis of breast lesions in medical images", Comput. Sci. Eng., vol. 2, no. 5, pp. 39–45, 2000.

[33] J. Wei, B. Sahiner, L. Hadjiiski, H. Chan, N. Petrick, M. Helvie, M. Roubidoux, J. Ge, C. Zhou, "Computer aided detection of breast masses on full field digital mammograms", Med. Phys., vol. 32, no. 9, pp. 2827–2837, 2005.

[34] E. D. Pisano, C. A. Gatsonis, M. J. Yaffe, R. E. Hendrick, A. N. A. Tosteson, D. G. Fryback, L.W. Bassett, J. K. Baum, E. F. Conant, R. A. Jong, M. Rebner, C. J. D'Orsi, "American college of radiology imaging network digital mammographic imaging screening trial: Objectives and methodology", Radiology, vol. 236, no. 2, pp. 404–412, 2005.

[35] Lei Zheng, Andrew K. Chan,"An artificial intelligent algorithm for tumor detection in screening mammogram", IEEE transactions on medical imaging, vol. 20, no. 7, 2001.

[36] Pragati Kapoor, Dr. S.V.A.V. Prasad, "Image Processing for Early Diagnosis of Breast Cancer Using Infrared Images" ,2010 IEEE.

[37] A Munawar, S Adabi, AI Ismail, MI Saripan, R Mahmood, WNL Wan Mahadi, R.S.A. Raja Abdullah, "Breast Cancer Detection Using Forward Scattering Radar Technique", 2008 IEEE International RF And Microwave Conference Proceedings.

[38] Yuanwei Jin, Jose M.F. Moura, Yi Jiang, Michael Wahl, He Zhu, Qiuhong He, "Breast cancer detection by time reversal imaging", IEEE international symposium on bio imaging April 2008.

[39] Bhagwati Charan Patel, Dr. G.R.Sinha, "Early Detection of Breast Cancer using Self Similar Fractal Method", International Journal of Computer Applications, Vol. 10– No. 4, 2010

[40] Alaa M. Elsayad, "Diagnosis of Breast Tumor using Boosted Decision Trees", ICGST-AIML Journal, Volume 10, Issue 1, 2010

[41] Lei Zheng, Andrew K. Chan, "An artificial intelligent algorithm for tumor detection inscreening mammogram", IEEE transactions on medical imaging, vol. 20, no. 7, 2001.

[42] Huai Li, Shih-Chung B.Lo, Yue Wang, Lisa Kinnand, Matthew T. Freedman, "A multiple circular path convolution neural network system for detection of mammographic masses", IEEE transactions on medical imaging, vol. 21, no, 2, 2002.

[43] H.P.Chan, N.Petrick, B.Sahiner,"Computer-aided breast cancer diagnosis", Artificial intelligence techniques in breast cancer diagnosis and prognosis, Series in machine perception and artificial intelligence,Vol.39, World Scientific Publishing Co.Pte.Ltd, 2000, pp. 179-264.

[44] M.J. Bottema, G.N.Lee, S.Lu, "Automatic image feature extraction for diagnosis and prognosis of breast cancer", Artificial intelligence techniques in breast cancer diagnosis and prognosis, Series in machine perception and artificial intelligence, Vol.39, World Scientific Publishing Co.Pte.Ltd, 2000, pp. 17-54.

[45] S.Saheb Baha, Dr. K.Satya Prasad, "Morphological image processing in Bio- Medical Application", Proceedings of PCEAIFTOMM- International conference – PICA- 2006, held on 11th to 14th of July at Nagapur and NCBME-2006 – National conference on Bio-Medical Engineering held on 28th to 29th of March at Mumbai.

[46] S.Saheb Baha, Dr. K.Satya Prasad,"Automatic detection of Hard Exudates in Diabetic Retinopathy using MorphologicalSegmentation and Fuzzy Logic", in IJCSNS International Journal of Computer Science and Network Security, VOL.8 No.12, December 2008, pp. 211–218

[47] Rafael C. Gonzalez, Richard E. Woods, ADDISON-WESLEY, "Digtal Image Processing", An imprint of Pearson Education, 1st Edition.

[48] Nick Efford, ADDISON-WESLEY, "Digital Image Processing", An imprint of Pearson Education, 1st Edition.

ISSN : 2230-7109 (Online) | ISSN : 2230-9543 (Print)

Shabanam Tamboli received the Bachelors & Masters degree in electronic engineering from Shivaji University, Kolhapur, Maharaashtra. And registered for Ph.D. degrees at Vishwesharya Technological University, Belgaum, Karnataka in Electronics & Communication engineering. She is having total 10 years teaching experience. Her field of interest is Image Processing.

Viddulata Patil received Bachelors of Engineering degree from Shivaji University, Kolhapur. She is currently pursuing her Masters of Engineering Degree from Shivaji University. She is having 6 years teaching experience. And her area of interest is Analog Electronics Circuit Design and image processing.

Arifa Tamboli received the Bachelors & degree in Information Technology from Shivaji University, Kolhapur, Maharaashtra & Masters degree in Computer Science & Engineerin from Walchand College of Engineering, Sangli, Maharaashtra She is having total 6 years teaching experience. Her field of interest is Artifical Intelligence & Adhoc Network.